



PATIENT PRESENTING CLINICAL SIGNS

Sasha Palomino Presented with a history of distended abdomen per Owner. Dog has a history of elevated liver enzymes in the past but in the blood work performed today they are unremarkable.

SPECIES COMPUTED TOMOGRAPHIC STUDY OF THE ABDOMEN

Canine Plain and post contrast studies are available for review.

COMPUTED TOMOGRAPHIC FINDINGS

BREED
Shih Tzu The pancreas is mildly enlarged, uniform in attenuation with no evidence of steatosis, mass or peripancreatic inflammation.

SEX
FS Mild degenerative changes of the kidneys are seen bilaterally including corticomedullary rim signs and mildly hyperdense renal papillae.

AGE
10 The serosal fat presents normal attenuation behavior. There is no evidence of peritoneal effusion or peritonitis.

The adrenal glands are within normal limits for size, shape and organ architecture.

Both liver and spleen present with normal shape, even surface, uniformly attenuating parenchyma and homogeneous contrast enhancement, unremarkable.

INTERPRETED BY

Nele Eley (Ondreka),
DVM Dr. med. vet.,
DipECVDI

The position, delineation, wall and content of the gastrointestinal tract are considered within normal limits throughout.

The bony and surrounding soft tissue structures reveal no abnormalities.

COMPUTED TOMOGRAPHIC DIAGNOSIS

HOSPITAL NAME

Westchester Animal
Hospital

- Mild generalized pancreatic enlargement without concomitant peritonitis.
- Mild bilateral degenerative renal changes
- Otherwise unremarkable abdomen

REFERRING VET

Randy Dominguez

INTERPRETATION OF FINDINGS & FURTHER RECOMMENDATIONS

The mild pancreatic enlargement may be subclinical. However, chronic pancreatitis and age-related hyperplasia are possible differential diagnoses. Correlation with clinical and laboratory findings recommended.

INVOICE

23270

No abdominal masses or other significant abdominal pathology is detected.

DATE

12/17/2025



PATIENT

Sasha Palomino

SPECIES

Canine

BREED

Shih Tzu

SEX

FS

AGE

10

INTERPRETED BY

Nele Eley (Ondreka),
DVM Dr. med. vet.,
DipECVDI

HOSPITAL NAME

Westchester Animal
Hospital

REFERRING VET

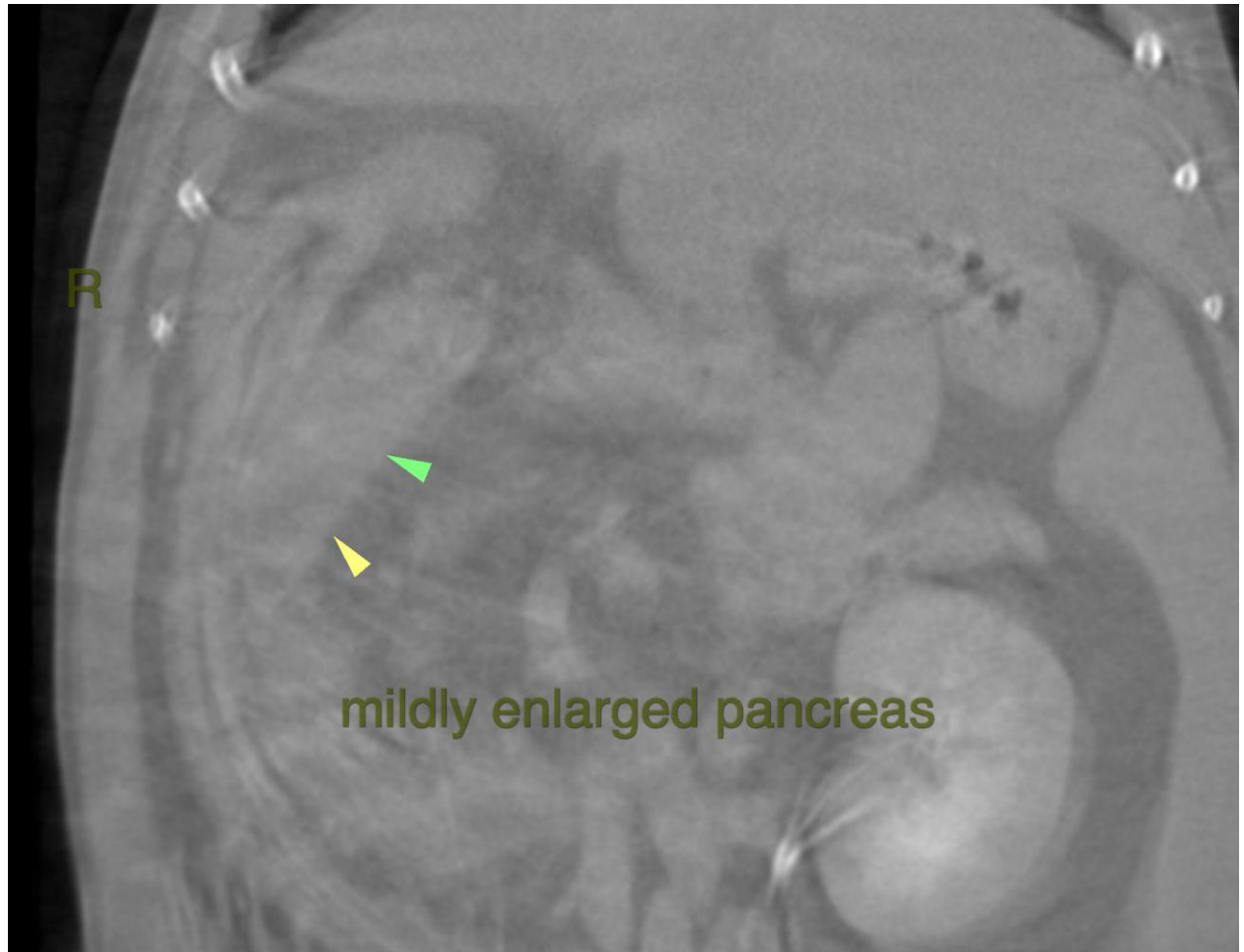
Randy Dominguez

INVOICE

23270

DATE

12/17/2025





PATIENT

Sasha Palomino

The information and recommendations provided are based on the images presented by the referring veterinarian. No evaluation can be communicated regarding pathology that was not visible in the image/video clips provided.

SPECIES

Canine

Thank you for this referral. If the clinical or image interpretation does not parallel your findings or if I can be of any further assistance please contact me.

BREED

Shih Tzu

Nele Eley (Ondreka), DVM, Dr. med. vet., DipECVDI
European Specialist in Veterinary Diagnostic Imaging, Cert. Radiology,
Senior lecturer University of Giessen/Germany, Veterinary Faculty, Department of Radiology.
info@sonopath.com

SEX

FS

AGE

10

INTERPRETED BY

Nele Eley (Ondreka),
DVM Dr. med. vet.,
DipECVDI

HOSPITAL NAME

Westchester Animal
Hospital

REFERRING VET

Randy Dominguez

INVOICE

23270

DATE

12/17/2025